

Surgical Procedures

Surgical Procedures For Treatment of Congenital and Acquired Heart Defects

Cardiovascular surgical procedures or operations may have one of several goals. **Anatomically corrective** procedures are required to make heart structures normal. **Physiologically corrective** procedures are required to separate and/or redirect the blue and pink blood circulations. These corrective procedures range from the relatively simple, such as closing or patching a hole or tying off a vessel, to the complex, such as switching vessels or rerouting blood streams. Most corrective operations require the use of a heart-lung machine, a cardio-pulmonary bypass pump. Some corrective surgical procedures provide complete correction of the normal physiology of the heart. Some corrective procedures provide an altered type of physiology of the heart and provide permanent palliation, such as the Fontan procedure.

Palliative procedures are required to improve, but not correct, an abnormal heart function. Palliative operations are performed to improve the heart function, usually in children too young for corrective surgery. The aim is to lessen cyanosis, to control heart failure, or to prepare the circulation for later repair.

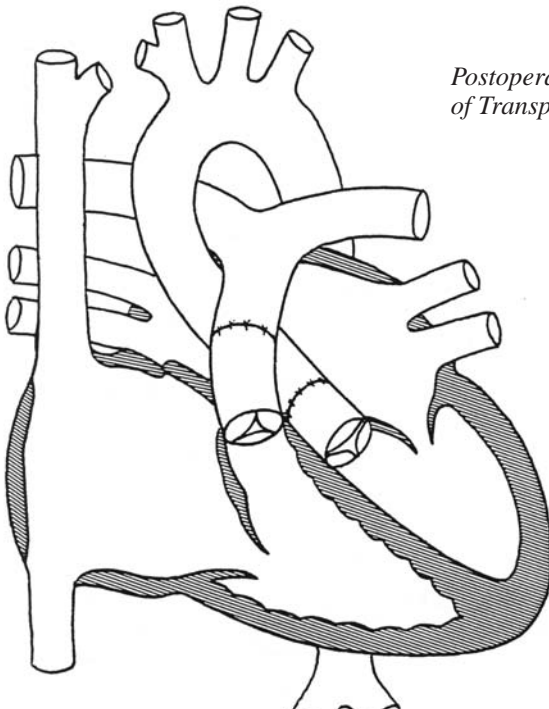
Few heart operations are truly corrective; usually some lifetime follow up is required. Most surgeries can restore the heart and vessels to near normal performance and extend the life span.

Cardiovascular operations require the chest to be opened under general anesthesia. The approach is either through the midline of the chest, called a median sternotomy, or from either side of the chest, called a lateral thoracotomy. Minimally invasive heart surgery using small incisions is gaining popularity and doctors are hopeful that endoscopic surgery will soon be available for some cardiac defects. Endoscopic surgery uses a viewing tube to examine and treat internal structures without opening the body surgically.

Some of the better-known heart operations are described below for quick reference. (See chapter on Congenital Heart Defects for the currently recommended surgical procedure appropriate to a specific defect.)

Arterial Switch

The Arterial Switch is the preferred anatomically corrective operation for both simple and complex forms of d-transposition of the great arteries because it restores the structure and the function of the heart to normal. The aorta and pulmonary artery are severed from their transposed origins and reconnected in such a way that they receive the correct blood from the correct ventricle. That is, after repair, the LV directs blood to the aorta and the RV sends blood to the LV. The arterial switch requires a separate transfer of the coronary arteries from the originally right-sided aortic stump to the new left-sided aortic root, the former pulmonary trunk.



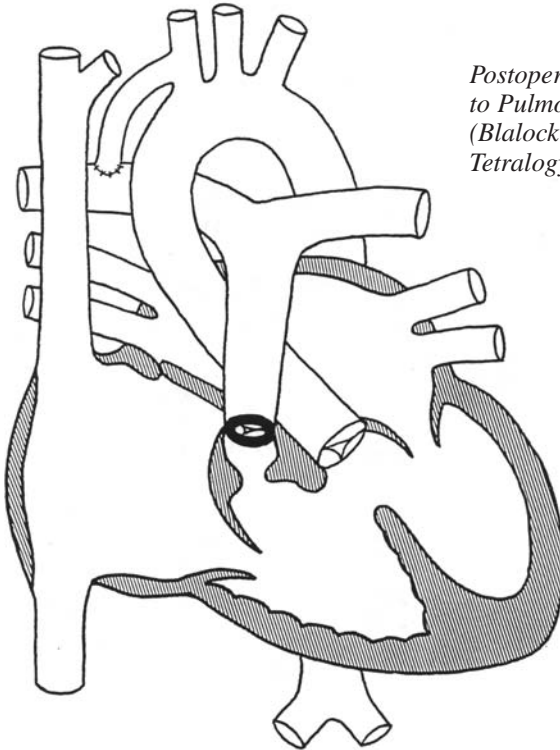
*Postoperative Arterial Switch Repair
of Transposition of the Great Arteries*

The Blalock-Hanlon Procedure (Creation of an Atrial Septal Defect)

This is a closed-heart operation aimed at improving the bluish cyanosis color in certain conditions such as transposition or tricuspid atresia. While complete separation of blue and pink circulations is normally desirable, in transposition and several other anomalies, the two circulations must mix within the heart for the child to do well. A hole in the atrial septum is an efficient way to accomplish such mixing. Eventually, anatomic or physiologic repair will follow.

The Blalock-Taussig or BT Shunt

Shunts are surgical connections, or anastomoses, between two arteries or between a vein and an artery. The Blalock-Taussig shunt connects a branch of the aorta, usually the subclavian artery, to the pulmonary artery directly or by using a plastic tube to increase the pulmonary blood flow.

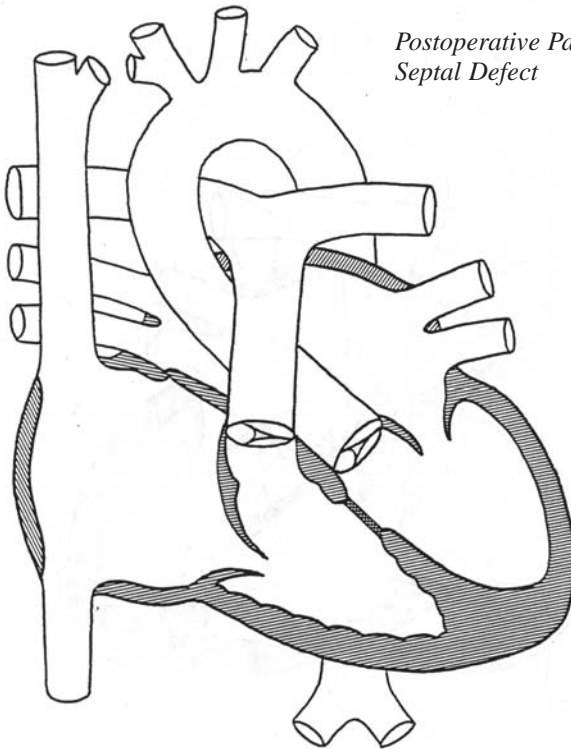


*Postoperative Subclavian Artery
to Pulmonary Artery Anastomosis
(Blalock-Taussig Shunt) for
Tetralogy of Fallot*



Closure of Septal Defects

Smaller atrial and ventricular septal defects can be closed with sutures or stitches. Larger defects require the use of a plastic patch. Occasionally, in complex defects, the patch is used not only to close the hole between the ventricles but also to channel left ventricular blood through the right ventricle into the aorta through an intracardiac tunnel.



Postoperative Patch Repair of Ventricular Septal Defect



Correction of Narrow Valves

The four valves in the heart can be narrow, stenosed, or regurgitant, leaky, or both. They can be either repaired or replaced, depending on the nature of the problem. The most common aortic and pulmonic stenosis is caused by congenital fusion of one or more moving valve leaflets. Repair is done using cardiopulmonary bypass and by cutting the fused leaflets apart. Occasionally, however, the seat of the valve, the annulus, is small, a condition called hypoplastic. Enlargement of the pulmonic annulus is accomplished by cutting it and placing a trans-annular patch across it. The resulting valve leak is usually well tolerated for a decade or more. A small aortic annulus cannot be enlarged without valve replacement because it would cause excessive regurgitation, or leaking. A regurgitant aortic valve can sometimes be repaired by tightening the loose leaflets in a procedure called a valvuloplasty). Narrow mitral or tricuspid valves can rarely be enlarged and usually need to be replaced. Regurgitant mitral or tricuspid valves can frequently be repaired by valvuloplasty.

Valves can be replaced by biological or prosthetic material. Biological valves are either homograft, taken from a human cadaver donor; or porcine, taken from a pig. There is a variety of prosthetic valves available. Many issues need to be considered when choosing the most suitable valve. Mechanical prosthetic valves will require a lifetime of clot-preventing medication, such as Coumadin or aspirin, and may not be ideal for females desiring to become pregnant. At this writing, an ideal valve has not yet been designed and most prosthetic valves will eventually need replacement.





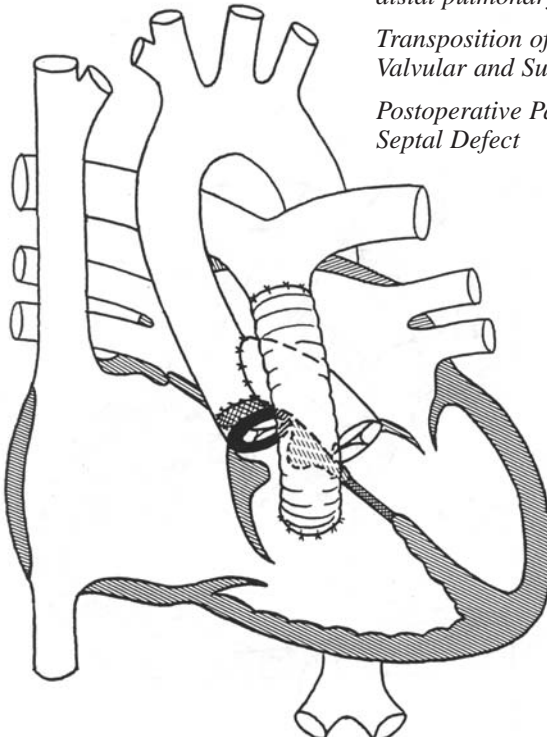
Damus-Kaye-Stansel Operation

This procedure usually complements other corrective procedures. It was originally developed along with the Rastelli procedure for correcting transposed great arteries with a VSD without switching them. It is now frequently employed as part of the Fontan operation in one-ventricle repairs to overcome any obstruction to the aortic blood flow. It consists of connecting the pulmonary trunk and the ascending aorta, and detaching the pulmonary artery branches. The pulmonary artery branches are supplied temporarily by an artificial shunt from the aortic branches. The aorta thus receives flow through both pulmonic and aortic valves.

Postoperative main pulmonary artery to ascending aorta (end-to-side) anastomosis with patch closure of aortic orifice (Damus-Kaye-Stansel operation) and conduit interposition from right ventricle to distal pulmonary artery (Rastelli repair) for:

Transposition of the Great Arteries with Valvular and Subvalvular Aortic Stenosis

Postoperative Patch Closure of Ventricular Septal Defect

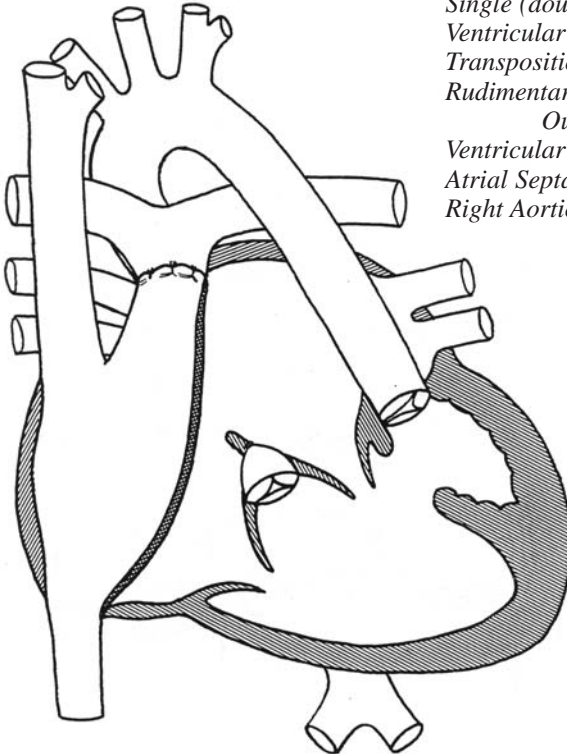




Fontan Operations

Many versions of this physiologically corrective procedure exist and they continue being updated. The Fontan operation is reserved for complex heart abnormalities that cannot undergo two-ventricle repair. Such hearts are grouped together as uni-ventricular, meaning that there is only one functional ventricle, which must be left to propel the pink blood to the body. The blue and pink circulations are surgically separated by atrial partition and the blue side – the IVC, inferior vena cava and SVC, superior vena cava – is connected directly to the pulmonary artery without any valves. There is no pump for the blue blood, but the circulation is nevertheless effective as long as the pressure in the lungs are low. The operation eliminates the bluish cyanosis and allows for reasonable physical activities.

Postoperative right atrial to pulmonary artery anastomosis with atrial “baffle” and ligation of proximal pulmonary artery (Fontan repair) for:
Single (double-inlet left) Ventricle
Ventricular Inversion
Transposition of the Great Arteries
Rudimentary Subaortic Right Ventricular Outflow Chamber
Ventricular Septal Defect (outlet foramen)
Atrial Septal Defect
Right Aortic Arch





Kawashima Operation

This intraventricular tunnel repair is used for anatomic correction of double outlet right ventricle where both the aorta and the pulmonary artery originate from the right ventricle and the only exit from the left ventricle is the ventricular septal defect. The ventricular septal defect is left open and sometimes even enlarged to serve as the mouth into a tunnel leading from the left ventricle through the right ventricle to the aorta. This tunnel is called an intracardiac conduit because it occurs completely within the heart. This tunnel is created in such a way as to separate the LV to the aorta and the RV flow to the pulmonary artery. This operation avoids the use of an extracardiac pulmonary conduit.



Ligation (Division) of Patent Ductus Arteriosus

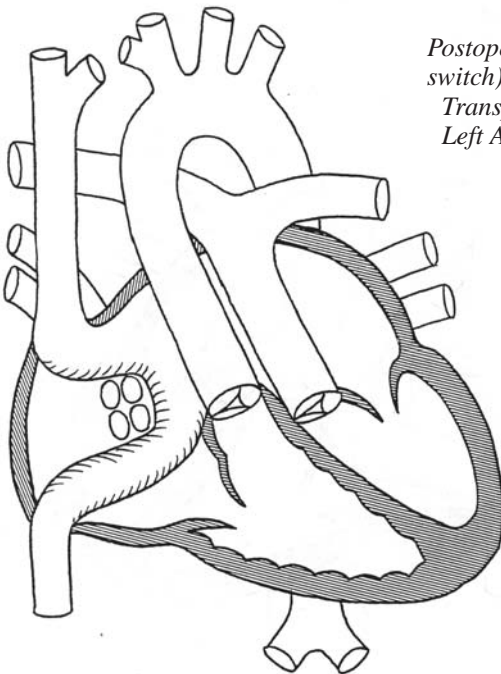
This is one of the truly corrective operations. Once the ductus is successfully closed, no further surgery is required. Ductal closure is a closed-heart procedure consisting of cutting the ductus and sewing up the two stumps. In tiny premature babies, ligation, or tying off, the ductus is preferred, although the ductus infrequently reopens.



Mustard Procedure

This procedure, also called a Venous Switch, is used for physiologic, or functional, correction of transposition of the great arteries (d-transposition). As with a similar procedure, called the Senning operation, the Mustard Procedure leaves the transposed origin of the aorta and pulmonary artery unchanged, and instead switches the blood streams entering into the atria. Thus, ultimately, the aorta receives the pink, oxygen-rich blood and the pulmonary artery carries the blue, oxygen-poor blood. This is accomplished by rerouting the blue veins from the right to the left atrium and the pink veins from the left to the right atrium using a partition or "baffle" harvested from the patient's own pericardium, the membranous sac that encloses the heart. The superior vena cava (SVC) and the inferior vena cava (IVC) are directed under the "baffle" into the left atrium (now carrying blue blood), left ventricle and pulmonary artery. The four pulmonary veins flow over the "baffle" into the right atrium, which now carries pink blood, and into the right ventricle and aorta.

This operation has been, to a large extent, replaced by the arterial switch operation.



Postoperative Mustard Repair (venous switch) for:

*Transposition of the Great Arteries
Left Aortic Arch*



Norwood Procedures

These procedures are used to treat hypoplastic left heart syndrome, a group of defects in which the left ventricle is very small or absent.

Norwood 1 is a palliative operation – a fix, not a cure – performed in newborns as an emergency procedure using cardiopulmonary bypass pump. It converts the functionally single right ventricle to act as the left ventricle while the pulmonary trunk is surgically joined with the tiny aorta to form a large new aorta, using a modified Damus-Kaye-Stansel procedure. The aortic arch is reconstructed as well, if necessary. The pulmonary artery branches are detached and connected to the new aorta by a small plastic tube, a procedure known as a modified Blalock-Taussig anastomosis. Norwood 1 enables an infant to grow to 4 to 10 months of age, when the second stage palliative operation can be undertaken.

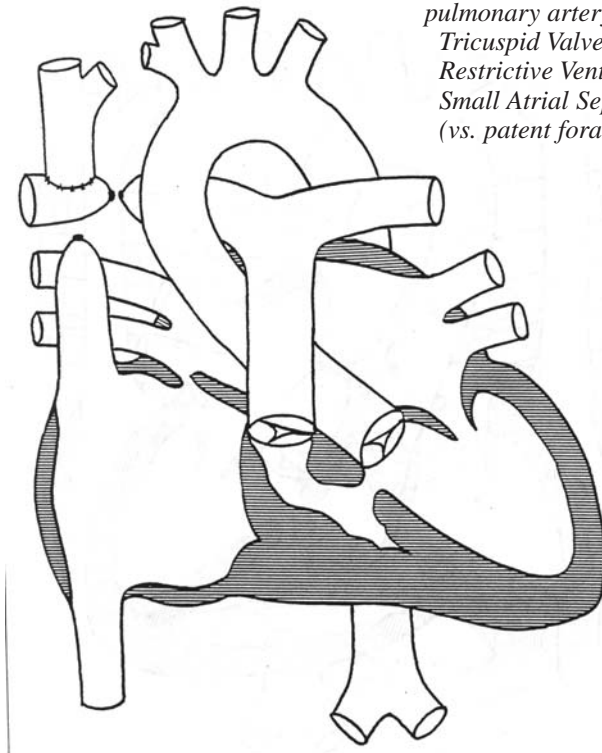
Norwood 2 converts the Blalock-Taussig anastomosis to a bi-directional Glenn or a Hemi-Fontan anastomosis in preparation for the eventual Fontan procedure, which is the corrective repair. The Glenn and the Hemi-Fontan, a version of the Glenn, consist of connecting both pulmonary artery branches to the superior vena cava, enabling the blue blood to reach the pulmonary circulation directly without having to pass through the heart chambers.

At a suitable age, around 18-24 months, the child becomes eligible for the Fontan operation, which eliminates cyanosis by directing the inferior vena cava to the pulmonary artery and partitioning the two atria.



One-and-One-Half Ventricle Repair

This procedure is used when the right ventricle is too small to handle the entire blue circulation, which ordinarily goes to the lungs for oxygenation. In this operation, the right ventricle is left to pump only the IVC (inferior vena cava) blood to the pulmonary artery, while the SVC (superior vena cava) blood reaches the pulmonary artery through the Glenn anastomosis.



*Postoperative superior vena cava to right pulmonary artery (Glenn anastomosis) for:
Tricuspid Valve Atresia
Restrictive Ventricular Septal Defect
Small Atrial Septal Defect
(vs. patent foramen ovale)*



Pulmonary Artery Banding

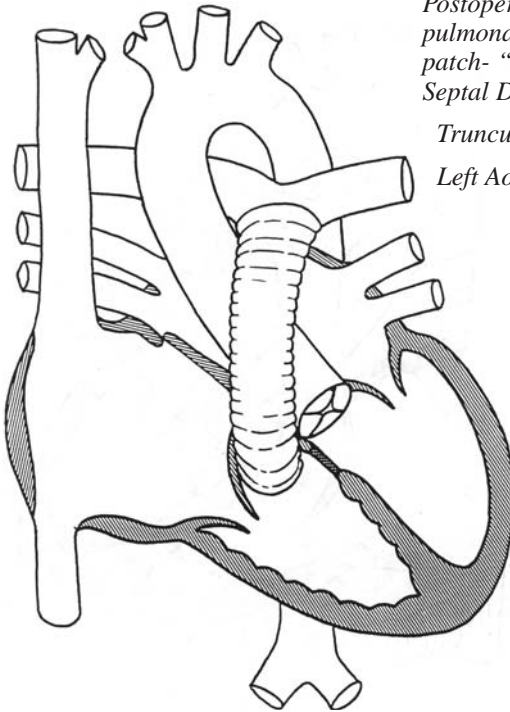
This is a temporary, palliative procedure that reduces excessive flow and pressure in the pulmonary artery. The pulmonary artery is surgically constricted using a wide tape to the point where heart failure due to excessive pulmonary blood flow is controlled. As the child grows, the banded artery remains the same size, causing the child's color to become bluer. At this point a corrective surgery may be carried out, or occasionally, a shunt will be placed to restore the pink color.



Rastelli Procedure

This is an anatomically corrective repair for heart defects that have in common a missing, defective, or obstructed pulmonary artery and a large ventricular septal defect. Truncus arteriosus and transposition of the great arteries, as well as other similar conditions, benefit from the Rastelli procedure.

Basically, the flow of blue blood to the lung circulation is established through a tube placed outside the heart, usually containing a valve. The large ventricular septal defect (VSD) is either closed with a patch or used to construct a new aortic outlet. The valve is placed from the right ventricle to the pulmonary artery. The VSD is closed in such a way as to separate the flow between the ventricles so that the RV flow goes to the pulmonary artery and the LV flow goes solely to the aorta. Such reconstructed hearts have all the components and function of the normal heart. However, the pulmonary conduit cannot grow with the child and eventually requires replacement.



Postoperative right ventricle to pulmonary artery conduit and patch- "baffle" repair of Ventricular Septal Defect (Rastelli repair) for:

*Truncus Arteriosus (type I and II)
Left Aortic Arch*



Repair of Anomalous Pulmonary Venous Return

Whether some or all four pulmonary veins are draining anomalously into a wrong cardiac structure, the aim of surgery is to re-connect them to the left atrium. If the veins are neither obstructed nor narrow before surgery, the result can be excellent. Obstructed veins, however, tend to re-narrow and may require additional operations.



Repair of Coarctation of the Aorta

This procedure usually does not require cardio-pulmonary bypass. A variety of surgical methods are currently in use. Resection, or removal, of the narrowing and an end-to-end anastomosis, a surgical connection of arteries to form a passage, is rarely used because of high recurrence rate. Instead, an extended end-to-end anastomosis offers good long-term repair by removing all the abnormal wall. The subclavian patch repair uses part of the left subclavian artery to enlarge the aortic narrowing, but a plastic patch can be used instead. Rarely is the narrow segment bypassed by a conduit or tube graft.



Repair of Common Atrio-Ventricular (AV) Canal

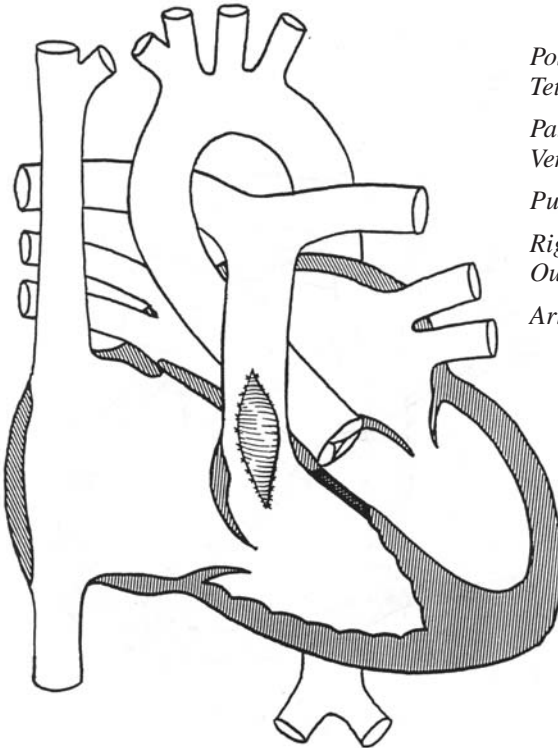
This anomaly consists of a large confluent atrial and ventricular septal defect and an undivided, or common, inlet valve. Although surgical techniques vary, repair requires patch closure of the two defects and separation of the common valve into a tricuspid and a mitral valve, called the two-ventricle repair. Rarely, when one of the ventricles is too small, a condition called an unbalanced AV canal, a one-ventricle repair, or Fontan operation, is preferable. A partial AV canal, also called an ostium primum defect, consists of a large atrial septal defect and a cleft, or regurgitant, mitral valve. Repair is accomplished by patch closure of the defect and suturing the cleft.



Repair of Tetralogy of Fallot

Tetralogy of Fallot, or blue baby disease, is repaired using a combination of ventricular septal defect closure and repair of narrowings along the pulmonary artery path. An angled patch placed over the large ventricular septal defect serves to channel left ventricular blood into the overriding, or straddling, aorta. Repair of pulmonary stenosis can involve sewing a patch in the right ventricular outflow tract, across the seat of the valve, pulmonary trunk and pulmonary artery branches. When either the pulmonary valve or the trunk is atretic, that is, completely blocked, the Rastelli conduit is required to complete the correction.

When the pulmonary artery is absent, small arteries originating from the aorta called Multiple Aorta Pulmonary Collateral Arteries, or MAPCAs, supply the lung circulation. This type of tetralogy requires multiple steps to correct. First, MAPCAs on the two sides need to be joined into a single vessel in two separate procedures, called unifocalization. Correction is eventually accomplished using the Rastelli repair:



Postoperative repair of Tetralogy of Fallot with:
Patch Closure of Ventricular Septal Defect
Pulmonary Valvectomy
Right Ventricular Outflow/main Pulmonary Artery Outflow Patch



Ross Procedure

This procedure consists of replacing a faulty aortic valve with the patient's own healthy pulmonic valve. It requires re-implantation of the coronary arteries into the reconstructed aortic root. The pulmonic valve is replaced with a biologic valve, either homograft taken from a human cadaver donor; or porcine, taken from a pig. This operation can be part of the Ross-Konno procedure employed when there is additional narrowing below the aortic valve. In the Konno procedure, the narrow left ventricular outlet is approached through the right ventricle, the septum is cut open, and filled with a large patch in such a way as to enlarge the LV outflow tract.